

Arthrodesis of the Hallux Interphalangeal Joint Using a Diagonally Placed 2-mm. Cortical Bone Screw

Arthrodesis of the interphalangeal joint of the hallux is quite often needed in conjunction with first metatarsophalangeal joint interpositional arthroplasty. With the exception of two cited techniques, the authors believe all previously described methods of achieving interphalangeal joint arthrodesis are inconsistent in their results and in their ability to be performed in conjunction with first metatarsophalangeal joint procedures. The authors, therefore, sought a more practical, efficacious method of achieving hallux interphalangeal joint arthrodesis in the presence of first metatarsophalangeal joint implants, while still using ASIF-AO compressive technique. Presented is their technique of hallux IPJ arthrodesis using a diagonally placed 2-mm. cortical bone screw.

Jared P. Frankel, DPM, FACFS^{1,2}
Robert Turf, DPM, FACFS²
Mark Tirone, DPM³

Arthrodesis of the interphalangeal joint (IPJ) of the hallux has classically been performed in the presence of IPJ symptomatology. These symptoms may present secondarily to conditions affecting the stability of the hallux, such as in: 1) sagittal plane deformities (hallux flexus, hallux extensus, hallux rigidus); 2) transverse and frontal plane deformities (hallux abductus, hallux adductus, hallux valgus, hallux varus); 3) prior sesamoidectomy with loss of intrinsic muscle function (1); and 4) prior arthrodesis of the first metatarsophalangeal joint (MPJ) (2). Conditions affecting the stability of the hallux, *i.e.*, above-mentioned deformities, often have deformities located at the IPJ. Arthrodesis of the IPJ is indicated in those patients where intrinsic muscle function has been compromised and digital and MPJ stability are lacking (3). A primary goal (other than providing relief of symptomatic lesions) of arthrodesis is to provide a stable lever on which the long and short flexors can function, to assist in first MPJ stability. Salvage procedures of the first MPJ may require joint interpositional arthroplasty while at the same time require hallux IPJ arthrodesis for correction of the distal IPJ deformity (4). The authors have found the currently described methods of achieving hallux IPJ fusion incompatible with procedures involving the hallux. Therefore, the authors sought a practical means of

achieving arthrodesis, while still using the ASIF-AO compression technique.

Review of Literature

Stabilization of the osseous fragments of the hallux while arthrodesis is occurring has been described in numerous ways in the literature (3, 5-8). These include Kirschner wire fixation (encompassing single and double variations), monofilament 28-gauge wire, 4-mm. cancellous bone screw, 3.5-mm. cortical bone screw, 2.7-mm cortical bone screw, and the Micks external fixator. Since the emergence of using these internal fixation methods, various evaluating studies have been performed that eventually lead to the accepted current method of ASIF-AO fixation (6).

Schives and Johnson (6) presented their Mayo Clinic study evaluating 166 cases of hallux IPJ arthrodesis, using Kirschner wire stabilization. They found pseudoarthrosis to be as high as 44% with this technique. Failure to obtain arthrodesis using Kirschner wire fixation may be attributed to the generalized concept that ultimately Kirschner wires do not afford interfragmentary compression. Although compression across the bony deficit is not needed to obtain repair, close proximity as well as immobilization/stability of these osseous segments is needed.

Massengill *et al.* (9) demonstrated that there is potential for distraction of the osseous segments with the divergent direction of two crossing Kirschner wires. Should this distraction occur, the position is lost because the fragments cannot glide along two different axes at the same time. Thus, the segments cannot

From the Department of Podiatric Surgery, Leyden Community Hospital, Northlake, Illinois.

¹ Director of Podiatric Surgical Residency.

² Diplomate, American Board of Podiatric Surgery.

³ Submitted while first year surgical resident. Address correspondence to: 135 E. North Avenue, Northlake, Illinois 60164.
0449/2544/89/2804-0466\$02.00/0

Copyright © 1989 by the American College of Foot Surgeons

approximate, and improper union would result. The above mentioned characteristics of Kirschner wires may account for the inconsistency obtained when using them for an IPJ arthrodesing procedure. Following Schrives and Johnson's (6) report of IPJ arthrodesis using Kirschner wire techniques, they presented a new technique of obtaining hallux IPJ fusion, with a longitudinally placed 4-mm. cancellous bone screw.

Subsequently, Schrives and Johnson reported a decrease in pseudoarthrosis incorporating the 4-mm. cancellous bone screw method. Although the original longitudinally placed 4-mm. cancellous screw did decrease the rate of pseudoarthrosis, various other complications (drawbacks) have been noted. Over-countersinking the distal phalanx (which appears to guard against screw head irritation) past the metaphyseal bone has been reported to cause interosseous screw migration (10). In the presence of insufficient distal tuft density (such as advanced rheumatoid arthritis), countersinking, even minimally, may cause interosseous screw migration. Interosseous screw migration will cause loss of interfragmental compression due to loss of a distal cortical surface needed to obtain compression. Once compression is lost, distraction of the osseous segments occurs, and a longitudinal screw actually aids in maintaining the segments distracted. Once compression is lost, and segments distract, the threaded portion of the screw within the proximal phalanx medullary canal may rotate, causing a medullary scraping within the canal. This can appear as a hollowing out, or cystic degeneration, surrounding the threaded part of the screw (Fig. 1).

Modifications of the original 4-mm. cancellous bone screw have been described using a 3.5-mm. cortical bone screw (3). The 3.5-mm. cortical screw was initially introduced on the premise that it was possible that insertion of a 4-mm. cancellous screw may cause stripping of the intramedullary canal of the base of the proximal phalanx. A second attempt at fixation may be attempted using the 3.5-mm. cortical bone screw. Also, the 3.5-mm. cortical screw may be removed more easily than the 4-mm. cancellous screw, due to the fact that the 4-mm. cancellous screw allows for bony ingrowth around the smooth shaft. Therefore, when retrograding upon removal of the screw, threads had to be cut in the distal phalanx, subsequently making removal difficult. Also, the actual size of the screw may be incompatible with the size of the distal phalanx. This can cause separation of the distal phalanx with interference of desired compression. Finally, a major consideration when using longitudinally placed cortical/cancellous bone screws is the fact that it occupies the medullary canal of the proximal phalanx, thereby negating its use for an adjunct procedure, namely interpositional arthroplasty of the first MPJ.

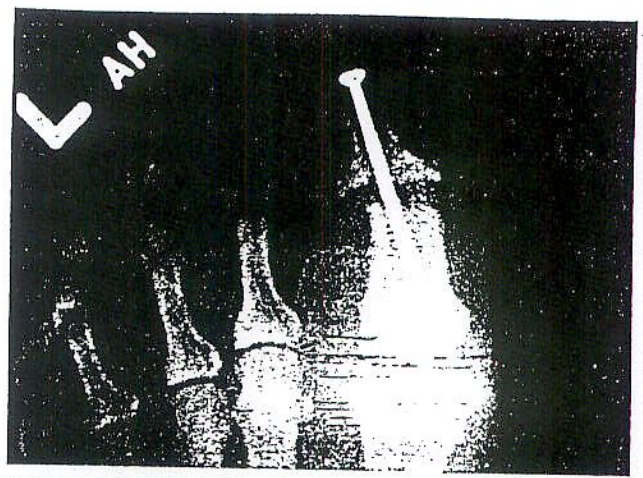


Figure 1. Attempted IPJ arthrodesis using a 4-mm. cancellous bone screw. Note the distraction of joint space with distal migration of screw and lucency of medullary canal (washing out) secondary to movement of threaded portion of screw.

Two references using compressive techniques have been cited in the literature dealing with obtaining IPJ arthrodesis in the presence of insignificant proximal phalangeal bone stock/medullary canal (5, 7). Gerbert (7) described use of the 2.7-mm. cortical bone screw oriented in a dorsal to plantar direction across the IPJ. The joint resection must be modified into the sagittal plane (as opposed to the standard transverse plane resection), so that there is adequate bone-to-bone contact with the screw in the vertical oblique axis. The authors have observed that resection of joint surfaces in the sagittal plane produce an increase in shortening of the hallux over that of resecting the joint space transversely in the transverse plane. Sharon and McClain (5) described the external Micks fixator to achieve IPJ arthrodesis (5). Although these authors have never employed this technique, they believe it may be cumbersome and unnecessary for use in the hallux.

Technique

The surgical approach for performing an IPJ arthrodesis using the 2-mm. cortical bone screw may vary in accordance with adjunct procedures. When the authors have performed this along with an MPJ arthroplasty, the standard dorsomedial incision is continued to the level of the IPJ, and a serpentine extension is made to the lateral nail fold. The incision is deepened with care to visualize the extensor hallucis longus tendon. The IPJ is then identified and the joint space entered through a transverse incision to the extensor hallucis longus tendon. The medial, lateral, and plantar collateral ligaments surrounding the IPJ are transected, thus exposing the head of the proximal phalanx into the surgical field. The base of the distal phalanx is then further freed of soft tissues.

Using an oscillating bone saw, the articular surfaces of the base of the distal phalanx and the head of the proximal phalanx are resected perpendicular to the nail plate (Fig. 2). These joint resection guidelines are used only in the absence of hallux osseous deformity (*i.e.*, hallux interphalangeus). If osseous deformity is present, accommodative changes are made in joint resection. The position of the resected surfaces are then inspected and temporary fixation is obtained using a 0.045-inch Kirschner wire, driven obliquely from proximal-medial to distal-lateral, and approximately at a 45-degree angle to the resected joint space (Fig. 3).

The authors then use their modification of the described AO technique of inserting a cortical bone screw using the oblique line of approach to cortical surfaces. First, a 2-mm. drill bit is placed perpendicular to the cortical surface of the proximal phalanx in the region of the desired screw head position. The cortex is penetrated and the drill bit withdrawn. The 2-mm. drill bit is then placed at the desired angle and distance to the osteotomy: approximately 0.3 cm. proximal and at approximately 25 degrees from the 0.045-inch Kirschner wire. The 2-mm. drill bit is then advanced. Care is taken not to transverse the osteotomy site. The 2-mm. drill bit is then withdrawn, and a 1.5-mm. drill bit is used to form the far cortex hole (care must be taken to maintain the original angle to the osteotomy). The 1.5-mm. drill bit is then withdrawn and the near cortex countersunk with a mini fragment set countersink. After measuring of the holes with a depth gauge, an 0.035-inch Kirschner wire is inserted to visualize the obtained angle. Maintaining this angle, the far cortex is tapped, using a 2-mm. mini fragment set tap. The site is then irrigated and the 2-mm. cortical bone screw of

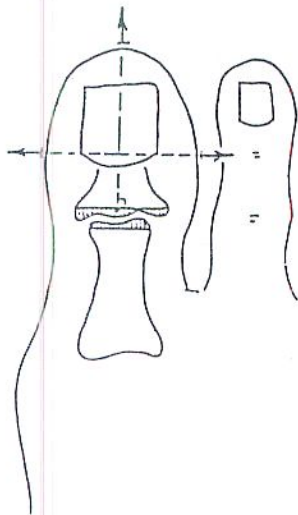


Figure 2. Articular cap resection made perpendicular to nail plate. Note: in presence of osseous deformity (*i.e.*, hallux interphalangeus) corrective modification in joint space resection may be used.

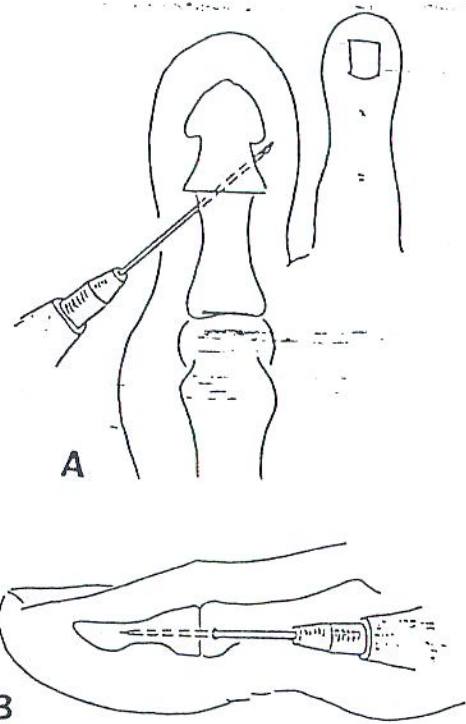


Figure 3. Temporary 0.045-inch Kirschner wire fixation placed at approximately 45 degrees to resected joint space A, anteroposterior; and B, lateral views. Note: care must be taken to place Kirschner wire as close to the distal medial border of the proximal phalanx, so that enough room is left for screw head placement.

appropriate length is inserted to two-finger tightness (Fig. 4). The Kirschner wire is then removed and the screw further tightened an additional $\frac{1}{4}$ -inch turn. The extensor hallucis longus tendon is appropriately reapproximated, and the incision site closed.

When performing this fusion technique with the interpositional arthroplasty of the first MPJ, the following order of procedures are followed: 1) preparation of medullary canal of proximal phalanx for acceptance of implant stem, 2) determination of appropriate implant size, 3) removal of implant sizer, 4) exposure of interphalangeal joint with arthrodesis using described technique, and 5) insertion of appropriate implant. The authors have used the 3D Short Leg Walker⁴ for immobilization for approximately 5 weeks, at which time a Mills dressing⁵ may be worn for an additional 2 weeks before returning to loose shoe wear.

Discussion

Salvage procedures of the first MPJ, such as revision surgery for hallux varus or correction of hallux rigidus, often require total joint interpositional first MPJ ar-

⁴ D Orthopedic Inc., Dallas, Texas.

⁵ Postsurgical Shoe, Paramount, California.

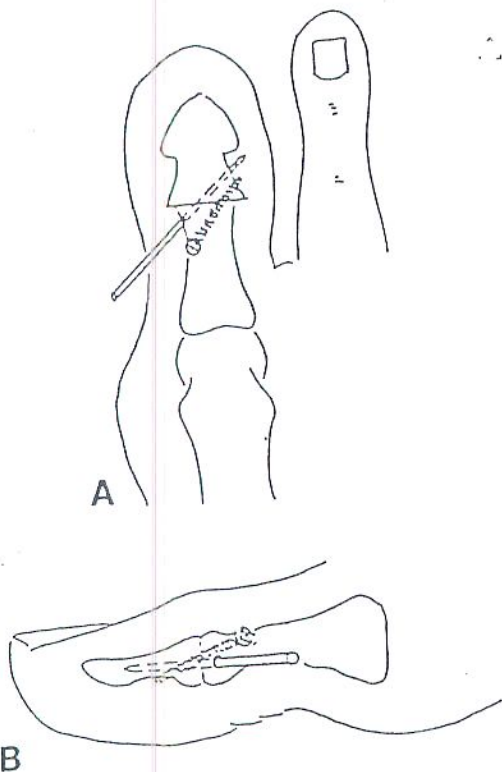


Figure 4. A, relationship of cortical screw to temporary Kirschner-wire fixation. Note: angle and distance from Kirschner wire. B, dorsal-to-plantar declination of screw. Note: dorsal position to temporary Kirschner wire fixation.

throplasty. A long-standing hallux varus often presents with severe degenerative changes located at the first MPJ due to the medial dislocation of the base of the proximal phalanx on the head of the first metatarsal. The use of first MPJ hinged implants are improvements (over the Keller arthroplasty) for maintenance of function and appearance in corrective hallux varus procedures (11).

Johnson (4) stated that a necessary adjunctive procedure for correction of hallux varus is arthrodesis of the IPJ of the great toe. They consider this necessary to correct the dynamic imbalance that can cause clawing of the hallux as the flexor hallucis longus overpowers the disadvantaged extensor hallucis longus. The authors have found that the combination of total sesamoidectomy, first MPJ hinged implant insertion, and arthrodesis of the IPJ provides maximum stabilization, preservation of function, and improvement of appearance of the hallux varus deformity. Arthrodesis of the IPJ with total sesamoidectomy has been performed by the authors prophylactically due to the high incidence of future cocking of the hallux at the IPJ (due to loss of intrinsic muscular stabilization). Hallux rigidus, end range-of-motion locking of the first MPJ, will translate necessary sagittal plane motion needed for walking to the distal available joint—the IPJ; thus producing ex-

cessive stress on this unsuspected joint. Results of this are severe IPJ degeneration and hallux flexus. Fusion of the IPJ, as well as total joint silicone arthroplasty, may be required to correct underlying first MPJ conditions.

The authors reported a method of achieving IPJ arthrodesis that combined diagonal placement (for preservation of the medullary canal of the proximal phalanx), plus the concept of static interfragmentary compression, *i.e.*, the diagonally placed 2-mm. cortical bone screw (Fig. 5).

Reliable bone stock is needed to achieve proper compression with screw fixation. With respect to the longitudinally placed AO technique, the critical regions of bone that will be used in compression are distal aspect of the distal tuft and metaphyseal subchondral cancellous bone, at the base of the proximal phalanx. Seldom is there significant cancellous bone in the proximal phalanx for satisfactory compression. If enough metaphyseal bone is present radiographically, one should be aware that it is likely to be soft and may preclude compression (10).

The authors have found the metaphyseal and diaphyseal regions of the proximal phalanx to vary greatly among patients, quite often being soft enough to be punctured with a blunt instrument. Thus, the authors believe the quality of bone stock within the metaphyseal region of the proximal phalanx is too variable to consistently produce good results with internal compression methods. The regions of bone involving diagonal

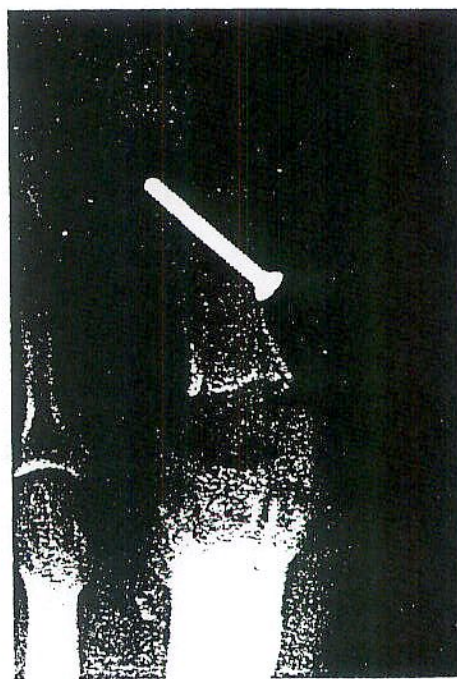


Figure 5. IPJ arthrodesis with 2.7-mm. cortical bone screw. Hinged implant in place.

compression methods are the medial cortex of the head of the proximal phalanx, and the lateral cortex of the base of the distal phalanx (Fig. 6). The cortices may be soft, and countersinking is therefore discouraged. The authors have found the lateral base of the distal phalanx are strong enough to hole the appropriate tap. These regions of the proximal phalanx and distal phalanx are consistent in their ability to accept AO compression devices.

Complications

Using the 2-mm. cortical bone screw for compression of an IPJ requires standard ASIF-AO technical ability of the surgeon. Complications have been encountered by the authors. First, the path of the screw must be transverse across the IPJ. Slight plantar declination is desirable (Fig. 4). However, excessive plantar lateral declination may cause the distal threads of the screw to skim along the plantar surface of the distal tuft, with compression being lost and dorsal gapping probable.

The temporary Kirschner wire fixation must be placed dorsally to avoid a region where the screw will be placed. Enough room must be left between the entrance of the Kirschner wire into the proximal phalanx and drilling of the near cortex. If underestimated, the screw head might impinge upon the Kirschner wire, and cause fracturing of the medial cortex of the proximal phalanx. The authors have found countersinking



Figure 6. IPJ arthrodesis with 2.7-mm cortical bone screw. Note the screw head at the medial cortex of head of proximal phalanx; and distal portion of screw at the lateral cortex of distal tuft.

usually unnecessary, due to the soft consistency of the cortex of the head of the proximal phalanx. A single lag screw creates a force of compression in line with the direction of the screw.

This basic principle of achieving rigid fixation with a single lag screw must be remembered. If the angle of the screw deviates from the plane of the osteotomy, there is a shift of the near fragment in the direction of the course of the screw as the screw is tightened and compression is created. The oblique direction of the cortical screw to the resected IPJ follows this principle.

Summary

The authors discussed their use of the diagonally placed 2-mm. cortical bone screw for arthrodesis of the hallux IPJ. Introduction of this procedure was based on the concept that often arthrodesis of the hallux IPJ is needed in conjunction with interpositional arthroplasty of the first MPJ. The authors have found this method of achieving fusion consistent in providing a solid, stable arthrodesis of the IPJ, as well as being able to be used with implants of the first MPJ.

Acknowledgment

The authors wish to thank Carl Ganio, DPM, for his contribution of illustrations.

References

1. Turner, R. S. Dynamic post-surgical hallux varus after lateral sesamoidectomy: treatment and prevention. *Orthopedics* 9:963, 1986.
2. Coughlin, M. J., Mann, R. A. Arthrodesis of the first metatarsophalangeal joint as a salvage for the failed Keller procedure. *J. Bone Joint Surg.* 69A:68, 1987.
3. McGlamry, E. D. (ed) *Comprehensive Textbook of Foot Surgery*. 1st ed., vol. 1, pp. 81, 192-194, Williams & Wilkins, Baltimore, 1987.
4. Johnson, K. A. Extensor hallucis longus transfer for hallux varus. *J. Bone Joint Surg.* 66A:681, 1984.
5. Sharon, S. M., McClain, J. An alternative fixation technique when performing hallux interphalangeal joint fusion. *J. Foot Surg.* 24:132, 1985.
6. Schrives, T. C., Johnson, K. A. Arthrodesis of the interphalangeal joint of the great toe: an improved technique. *Foot Ankle* 1:26, 1980.
7. Gerbert, J. Digital arthrodesis. *Clin Podiatr.* 2:1, 1985.
8. Mann, R. A., DuVries, H. L. Major surgical procedures for disorders of the forefoot. In *DuVries Surgery of the Foot*, 4th ed., pp. 590-592, edited by R. A. Mann, C. V. Mosby, St. Louis, 1978.
9. Massengil, J., Alexander, H., Parson, J., Schecter, M. Mechanical analysis of Kirschner wire fixation in a phalangeal model. *J. Hand Surg.* 4:351-356, 1979.
10. Schuberth, J. M. Pedal fusion in the rheumatoid patient. *Clin. Podiatr. Med. Surg.* 5:227-247, 1988.
11. Feinstein, M. N., Brown, H. N. Hallux adductus as a surgical complication. *J. Foot Surg.* 19:207, 1980.